

RESEARCH ARTICLE

Breast Imaging Using Electrical Impedance Tomography: Correlation of Quantitative Assessment with Visual Interpretation

Norhayati Mohd Zain¹, Kanaga Kumari Chelliah^{2*}

Abstract

Background: Electrical impedance tomography (EIT) is a new non-invasive, mobile screening method which does not use ionizing radiation to the human breast; allows conducting quantitative assessment of the images besides the visual interpretation. The aim of this study was to correlate the quantitative assessment and visual interpretation of breast electrical impedance tomographs and associated factors. **Materials and Methods:** One hundred and fifty mammography patients above 40 years and undergoing EIT were chosen using convenient sampling. Visual interpretation of the images was carried out by a radiologist with minimum of three years experience using the breast imaging - electrical impedance (BI-EIM) classification for detection of abnormalities. A set of thirty blinded EIT images were reinterpreted to determine the intra-rater reliability using kappa. Quantitative assessment was by comparison of the breast average electric conductivity with the norm and correlations with visual interpretation of the images were determined using Chi-square. One-way ANOVA was used to compare the mean electrical conductivity between groups and t-test was used for comparisons with pre-existing Caucasians statistics. Independent t-tests were applied to compare the mean electrical conductivity of women with factors like exogenous hormone use and family history of breast cancer. **Results:** The mean electrical conductivity of Malaysian women was significantly lower than that of Caucasians ($p < 0.05$). Quantitative assessment of electrical impedance tomography was significantly related with visual interpretation of images of the breast ($p < 0.05$). **Conclusions:** Quantitative assessment of electrical impedance tomography images was significantly related with visual interpretation.

Keywords: Electrical impedance tomography - visual interpretation - quantitative assessment

Asian Pac J Cancer Prev, 15 (3), 1327-1331

Introduction

Breast cancer is the most universal malignant tumor among women in the western (Zou and Guo, 2003). Hassan et al. (2011) mentioned that breast cancer is anticipated to be responsible for almost 40,000 death in United States. Breast cancer is considered to be the final outcome of multiple environmental and hereditary factors and therefore the best way to prevent mortality is by early detection. Currently, mammography (MMG) is the standard screening technique for breast cancer detection (Myoung et al., 2007). However, it has some limitations including the usage of ionizing radiation and causes patient's discomfort due to compression of the breast tissues. Moreover, it reduced ability to detect carcinoma in women with dense breast tissue (Prasad et al., 2008).

Ultrasound (US) is the most important adjunct imaging modality to localize and differentiate cyst from solid masses and it has undergone significant improvements that have extended its efficacy for breast imaging (Subbhuraam et al., 2011). Magnetic resonance imaging (MRI) of

the breast offers valuable information of breast cancer staging as it has a higher spatial and temporal resolution and a better signal to noise ratio (Lehman et al., 2005). Contrast-enhanced spectral mammography (CESM) technology allows visualization of contrast-enhanced areas of blood flow through angiography of the breast using intravenous iodine contrast agent. The contrast helps visualize localized increased blood flow pointing to areas of potentially cancerous lesions (Dromain et al., 2006).

EIT is a potential, new noninvasive diagnostic technique for imaging the human breast. The principles of EIT is based on the different electrical storage potential of normal and pathologically altered tissues allowing image differences in the tissue conductivity and permittivity inferred from the body surface electrical measurements. Literature shows that the electrical properties differ between normal and malignant breast tissues setting the stage for cancer detection through determination of electrical properties. Malignant tumors show substantially increased capacitance and conductance values resulting in

¹Diagnostic Imaging and Radiotherapy, School of Medical Imaging, Faculty of Health Sciences, KPJ Healthcare University College, Negeri Sembilan, ²Medical Physics, Faculty of Health Sciences, University Kebangsaan Malaysia, Jalan Raja Muda Abdul Aziz, Kuala Lumpur, Malaysia *For correspondence: kanagakk@yahoo.com

decrease impedance (Jossinet, 1996; Abdi et al., 2011).

An earlier study by Malich et al. (2001) stated that the sensitivity of EIT in detecting lesions is 88%. A study by Prasad et al. (2008) conducted on a population of women in Washington DC; Rochester NY; Pittsburgh and Israel stated that sensitivity was in the range of 75.1-91.0% whilst a study by Renata et al. (2012) on women from Slovakia found that the sensitivity was 87% in agreement with Pak et al. (2012). Chakraborti et al. (2010) reported that EIT was encouraging as the non-invasive screening method as there was significant association between sensitivity, specificity and age.

The electrical impedance method, compared to other imaging techniques allows conducting quantitative analysis of the visual images. The quantitative analysis of electric impedance images involves calculation of the mean electrical conductivity index, the histogram of electrical distribution and the results of comparative analysis with the reference (norm) data. The norm values are represented as a complex histogram of electrical conductivity distribution, which takes into account current season, age, parity, physiological period and the peculiarities of the examination.

When the mammary gland is not involved in any pathologist process, the histogram of the electrical conductivity distribution practically coincides with the norm; the divergence is less than 40%. When it is affected by a disease, the divergence is 40% and above (Korotkova and Karpov, 2007). Thus, this study has been designed to compare the quantitative assessment value of EIT images with its visual interpretation.

Materials and Methods

Data collection

The study was conducted at the University Kebangsaan Malaysia Medical Center, Kuala Lumpur, for the duration of 1 year. The study commenced after approval from the institutional review board (NN-136-2011) and informed consent was obtained from the patients prior to scanning. A group of 150 women above 40 years were chosen using convenience sampling underwent EIT screening.

Women who participated in this study filled out a demographic form on personal data and risk factors. Subjects were then divided into three groups of age; below 50 years, 50 to 60 years, and above 60 years old. Women who have had any breast surgery and breastfed their babies were excluded from this study. EIT screening was done using the electrical impedance computer mammograph MEIK developed by the Institute of Radio Engineering and Electronics, Russian Academy of Sciences consisting 256 electrodes with electrical current applied at 0.5 mA, 50 KHz.

The EIT examination

The EIT system consists of a portable PC, a transducer with 256 electrodes arranged in square matrix with a 12 cm side protrude which is positioned over the breast tissue, a source of alternating (AC) current, two additional electrodes; one electrode is connected directly to AC source and the other electrode is connected directly to

a potential difference detector. Each can be located on a patients' wrist (Figure 1).

The results are processed by a computer to produce reconstructed tomographic 2D or 3D images of the impedance distribution within the breast. Both static and dynamic imagings are available through EIT. Static imaging involves producing an image through the distribution of absolute conductivity or impedivity, while the dynamic imaging reconstruct images of change in conductivity, derived from a change in electrode voltages (Boone et al., 1997).

On the data acquisition, a 10 KHz ac current source, about 1mA, is connected between the remotely attached current electrode and one of the electrodes in the planar array. The potential difference between the selected at rest electrode in the planar array and the remote reference electrode is measured. The input electrode is switched and the output multiplexer sequence repeated, resulting in 65,280 (256×256) voltage measurements for each full measurement cycle. Images for 3D conductivity distribution are reconstructed using a modified back projection method (Cherpenin et al., 2002).

The examination was performed with the subject recumbent, similar to the position generally used during breast ultrasonography examination, with both arms raised above the head. The purpose of this position was to flatten the breast as much as possible, allowing optimal contact of the flat surface of the scan probe with the breast tissue. During examination, the transducer is firmly pressed against the breast and the probe was moved in such a way as to remove air bubbles and to ensure good contact with the breast. The image obtained was saved for interpretation.

Data analysis

The visual interpretation of EIT images was conducted by a radiologist with minimum of three years experience using BI-EIM classification. A set of thirty blinded EIT images was reinterpreted to determine the intra-rater reliability or consistency in the reporting using Kappa value. $\kappa \geq 0.8$ was considered perfect, $\kappa = 0.61-0.8$ was considered good, $\kappa = 0.41-0.60$ was considered moderate, $\kappa = 0.21-0.40$ was considered fair, and $\kappa \leq 0.20$ was



Figure 1. The Electrical Impedance Computer Mammograph MEIK Device Consists of a Portable PC, A Transducer with 256 Electrodes Arranged in Square Matrix

considered poor.

Visual evaluation involves the analysis of the breast contour, anatomy of the breast, local changes of electrical conductivity and lactiferous sinus zone. BI-EIM score for normal images is zero to one points (lesions is not defined) whilst score of two points and above (2-4: probably benign findings; 5-7: suspicious abnormality; 8-10: highly suggestive of malignancy) reflect as abnormal images. The quantitative assessment; the divergence value between the examined breast with the normal breast histogram were collected with divergence value less than 40% reflect as normal images whilst divergence value 40% and above reflect as abnormal images (Figure 2). A Chi-square was used to see the correlation between the quantitative assessments of the breast with visual interpretation.

Mean electrical conductivity value for each age group was collected and the significant difference between the age groups was determined using one-way ANOVA. T-test was used to compare the value with Caucasians; the average index of electrical conductivity for Caucasian women aged below 50 years is 0.35; women aged 50 to 60 years is 0.43 whilst women aged above 60 is 0.48 (Korotkova and Karpov, 2007). Independent t-test was used to compare the value of women in the risk factors group; exogenous hormone use and family history of breast cancer. All analyses was performed using the software Statistical Packages for the Social Sciences, SPSS version 19.0 (SPSS Inc., Chicago, IL, U.S.A.) and all statistical tests were two-sided with a p value <0.05 were considered significant.

Results

The total number of patients involved in this study was one hundred and fifty with an age range of 40 to 65 years (Table 1). Kappa intra-rater agreement was $k=0.864$. Malaysian women scored a mean electrical conductivity significantly lower than the Caucasian's standard value ($p<0.05$). There were no significant difference in mean electrical conductivity of value of women in the risk factors group; exogenous hormone use ($p=0.186$) and family history of breast cancer ($p=0.909$).

Table 2. Breast Abnormalities Found in Electrical Impedance Tomography

Breast Abnormalities	(n=61)
Cyst	17
Fibroadenoma	11
Benign pathology	24
Malignant pathology	9

Table 3. Electrical Conductivity Dispersion in Tissues

Type of tissue	Electrical conductivity, cu
Adipose tissue	<0.20
Scars, septa	0.20-0.30
Parenchyma	0.4
Fibroadenoma	0.50-0.55
Cyst	0.65-0.70
Cancer	>0.95

cu: conventional unit

Table 1. Demographic Characteristics of the Subjects (n =150)

		<50 years n (35)	50-60 years n (70)	>60 years n (45)	Mean electrical conductivity	p value
Menopausal status	Premenopausal	26 (74.3%)	13 (18.6%)	0 (0%)	0.293	
	Postmenopausal	9 (25.7%)	57 (81.4%)	45 (100%)	0.339	
Hormone use (Premenopausal)	Using oral contraceptives/hormones associated with IUD	8 (30.8%)	7 (53.8%)	0 (0%)	0.312	0.186
	Not using hormone	18 (69.2%)	6 (46.2%)	0 (0%)	0.279	
Hormone use (Postmenopausal)	Using HRT	6 (66.7%)	19 (33.3%)	9 (20%)	0.349	0.186
	Not Using HRT	3 (33.3%)	38 (66.7%)	36 (80%)	0.334	
Family history	No first-degree relative with breast cancer	25 (71.4%)	43 (61.4%)	41 (91.1%)	0.327	0.909
	1 first-degree relative with breast cancer	9 (25.7%)	26 (37.1%)	4 (8.9%)	0.324	
	≥ 2 first-degree relative with breast cancer	1 (2.9%)	1 (1.5%)	0 (0%)	0.3	
Mean Difference for Malaysian and Caucasians women		-0.065 ^a	-0.098 ^b	-0.114 ^c	0.331	<0.05*

*p<0.05 showed significant analysis; IUD: Intrauterine device; HRT: Hormone replacement therapy; ^a: Test value 0.35; ^b: Test value 0.43; ^c: Test value 0.48

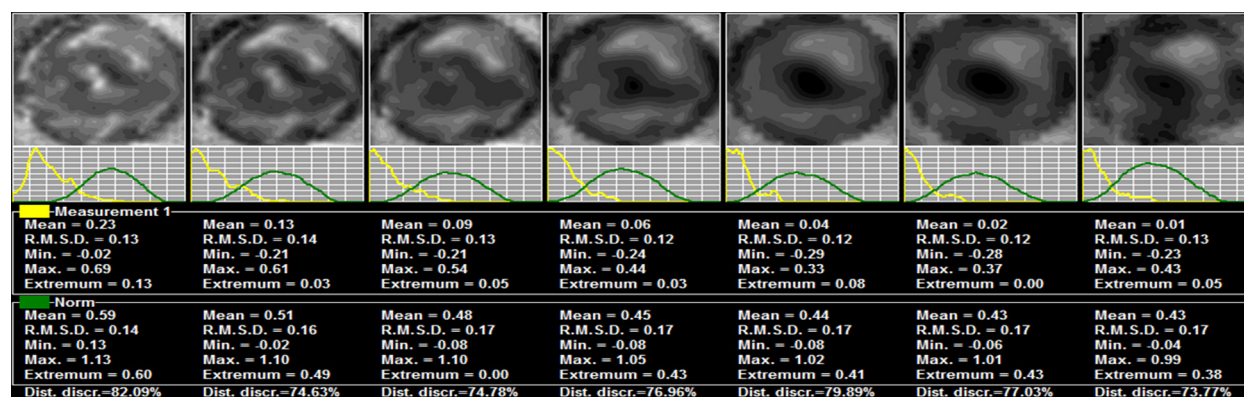


Figure 2. EIT Seven Scan Planes. The comparison of electrical conductivity index of the breast with norm (the first line showed the tomograms, the second the histograms of electrical conductivity distribution compared to the norm, the third-mean electrical conductivity index, R.M.S.D.-standard deviation, Min. - minimum conductivity index, Max.-maximum conductivity index, Extremum-the most frequent value of electrical conductivity, Dist. discr.-divergence value between histograms

There were 167 cases interpreted consistently visually as well as quantitative assessment using a Chi-square test. Breast abnormalities found in EIT are shown in Table 2. The quantitative assessment of EIT images was significantly related ($p < 0.05$) with visual interpretation, thus we expected 72 cases as normal at the same time 75 cases as an abnormal.

Discussion

EIT is able to decipher an anatomical structure as different tissues within the human body that has different electrical properties. The conductivity and permittivity of breast tumors have been studied and found to differ significantly from normal breast tissues. Dielectric properties of breast tissues studied on the impedance measurements of breast tissues were used to distinguish carcinomas from normal and benign tumors (Jossinet, 1996; Abdi et al., 2011). When probing the breast with an alternating current with 50 kHz frequency the dispersion of electrical conductivity is observed due to the different impedance of breast tissues (Table 3).

Our study has found that mean electrical conductivity value of Malaysian women were increased with age in conformity with researches such as Stojadinovic et al. (2005) and Korotkova et al. (2007) who stated that conductivity of electric tends to increase whilst breast electrical impedance tends to decrease with age.

However, it was significantly lower ($p < 0.05$) than Caucasians. Deurenberg et al. (2002) stated that Asians had a lower BMI compared to Caucasians thus Spearman's rho indicated the presence of a strong positive correlation between ranked BMI and mean electrical conductivity value ($r_s = 0.28$, $p = 0.001$) in current study in agreement with Wang et al. (1995) in a study of body compositions stated that there was significant difference in BIA measurements by race, stature and weight.

It was proven that the mean electrical conductivity of breast tissue shows no significant association with hormonal status contrary to Malich et al. (2001). The values of conductance and capacitance depend critically on the pressure between breast and scanner and vary, thus, examiner reliant. Contacts problems occurred mainly due to the inflexible scanner size in relation to small breasts and on peripheral lesions. Lesions were difficult to interpret especially when located close to the chest wall due to contact problems and close to the nipple due to the bright signal of the nipple itself.

Around half (55%) of total sample were interpreted as normal. However, the proportion of histogram divergence value less than 40 percent (65.6%) within this category is more than the proportion of histogram divergence value 40 percent and above. This showed that EIT potential to be used as an adjunctive examination in screening human breast with minimal costs (Malich et al., 2001; Renata et al., 2013).

It is worth noting that during the analysis of the data it cannot be excluded that lack of expertise to conduct screening and interpret EIT images at a local level caused a delay in the study. Continuous training of experts to conduct screening and interpret of the images is required

locally to determine the precise validity of EIT to be used as a potential screening tool.

In conclusion, the electrical conductivity ($M = 0.331$, $SD = 0.105$) of breast in Malaysian women was significantly lower than the standard Caucasians ($p < 0.05$). There was a significant correlation between the quantitative assessments with visual interpretation of EIT images. However, further studies are warranted to confirm our results.

Acknowledgements

The authors would like to express their sincere gratitude to Yang Berbahagia Dato' Dr. Mohan Singh from Daya X-ray Center, Kuala Lumpur, Dr. Marina Korotkova and Dr. Alexander Karpov from Clinical Hospital, Yaroslavl, Russian Federation for their co-operation in this research and to Mobecom Company, Kuala Lumpur that provided assistance in manpower and equipment support for the EIT.

References

- Abdi M, Liatsis P (2011). EIT in breast cancer imaging: application to patient-specific forward model. *Proceeding-4th International Conference on Developments in eSystems Engineering*, art. no. 6149955, 56-61.
- Ardrey DB, Murphy EK, Isaacson D, Saulnier GJ, Newell JC (2011). Electrical impedance tomography using the finite element method in the mammography geometry. *IEEE 37th Annual Northeast Bioengineering Conference, NEBEC 2011*, art. no. 5778563.
- Boone K, Barber D, Brown B (1997). Imaging with electricity: report of the European concerted action on impedance tomography. *J Med Eng Technol*, **21**, 201-32.
- Chakraborti KL, Selvamurthy W (2010). Clinical application of electrical impedance tomography in the present health scenario of India. *J Phys: Conf Ser*, **224**, 12069.
- Cherpenin VA, Karpov AY, Korjnevsky AV (2002). Three-dimensional EIT imaging of breast tissues: system design and clinical testing. *IEEE Trans Med Imaging*, **21**, 662-7.
- Deurenberg P, Deurenber-Yap M, Guricci S (2002). Asians are different from Caucasians and from each other in their body mass index/body fat per cent relationship. *Obes Rev*, **3**, 141-6.
- Dromain C, Balleyguire C, Muller S, et al (2006). Evaluation of tumor angiogenesis of breast carcinoma using contrast-enhanced digital mammography. *Am J Roentgenol*, **187**, 528-37.
- Hassan AM, El-Shenawee M (2011). Review of electromagnetic techniques for breast cancer detection. *IEEE Rev Biomed Eng*, **4**, 103-18.
- Jossinet J (1996). Variability of impedivity in normal and pathological breast tissue. *Med Biol Eng Comput*, **34**, 346-50.
- Korotkova M, Karpov A (2007). Procedure of assessment of the mammary gland electrical impedance images. *IFMBE Proc*, **17**, 699-702.
- Lehman CD, Schnall MD (2005). Imaging in breast cancer: magnetic resonance imaging. *Breast Cancer Res*, **7**, 215-9.
- Malich A, Bohm M, Facius M, et al (2001). Additional value of electrical impedance scanning: experience of 240 histologically-proven breast lesions. *Eur J Cancer*, **37**, 2324-30.
- Myoung HC, Kao TJ, David I, et al (2007). A reconstruction algorithm for breast cancer imaging with electrical

- impedance tomography in mammography geometry. *IEEE Trans Biomed Eng*, **54**, 700-10.
- Pak DD, Rozhkova NI, Kireeva MN, et al (2012). Diagnosis of breast cancer using electrical impedance tomography. *Biomedical Engineering*, **46**, 154-7.
- Prasad SN, Houskova D, Campbell J (2008). Breast imaging using 3D electrical impedance tomography. *Biomed Pub Med Fac Univ Palachy Olomouc Czech Repub*, **152**, 151-4.
- Renata O, Bella V, Bellova L, Zamecnikova E (2013). The use of electrical impedance tomography to the mammographic/sonographic findings. *Neoplasma*, **60**, 647-54.
- Renata O, Ondruš D, Bella V (2012). Utilisation of electrical impedance tomography in breast cancer diagnosis. *Clin Oncol*, **25**, 36-41.
- Stojadinovic A, Nissan A, Gallimidi Z, et al (2005). Electrical impedance scanning for the early detection of breast cancer in young women: preliminary results of a multicenter prospective clinical trial. *J Clin Oncol*, **23**, 2703-15.
- Subbhuraam VS, Eddie NYK, Rajendra UA, et al (2011). Breast imaging: a survey. *World J Clin Oncol*, **2**, 171-8.
- Wang J, Thornton JC, Burastero S, et al (1995). Bio-impedance analysis for estimation of total body potassium, total body water, and fat-free mass in white, black, and Asians adults. *Am J Hum Biol*, **7**, 33-40.
- Zou Y, Guo Z (2003). A review of electrical impedance techniques for breast cancer detection. *Med Eng Phys*, **25**, 79-90.